DEPARTMENT OF COMPUTER & SOFTWARE ENGINEERING

COLLEGE OF E&ME, NUST, RAWALPINDI

COURSE NAME

EC-312 Digital Image Processing

Assignment 01 Report

Connected Component Labelling based Segmentation

Submitted To:

Professor Dr. Asad Mansoor

Submitted By:

Usman Awan **REG # 480836**

DE - 45/SYN: A **DEPT: Computer Engineering**

Submission Date: 14/02/2026

Software Requirements: Python3, opencv, numpy.

Hardware Requirements: PC

No.	Contents	Page no.
1.	Problem overview	3
2.	Define V-set: - Preprocessing - Optic Disk (OD) V-set - Optic Cup (Cup) V-set	4
3.	Differentiate Components: - Differentiating OD - Differentiating Cup	6
4.	Flow Diagram	6
5.	Results - Dice coefficient calculation - Output images	7
6.	Conclusion	8

Problem Overview

Retinal fundus images are high-resolution photographs of the interior surface of the eye, captured to allow detailed examination of the optic nerve and retinal vessels. They are crucial in diagnosing various ocular pathologies, most notably Glaucoma, a chronic eye disease that leads to irreversible blindness due to optic nerve damage. Glaucoma is often characterized by the pathological enlargement of the optic cup relative to the optic disc, a metric known as the Cup-to-Disc Ratio (CDR). Early detection of these morphological changes is vital for preventing vision loss. Automated segmentation of the Optic Nerve Head (ONH) is essential for calculating the CDR and assisting clinicians in mass screening programs. In this assignment, we will implement Connected Component Labeling (CCL) for segmenting the nested structures of the optic nerve. The dataset consists of retinal fundus images with corresponding masks that classify each pixel into different categories:

1) Optic Cup (Inner Brightest Core)
2) Optic Disc (Outer Complete Disc)
3) Background (Retina & Corners)

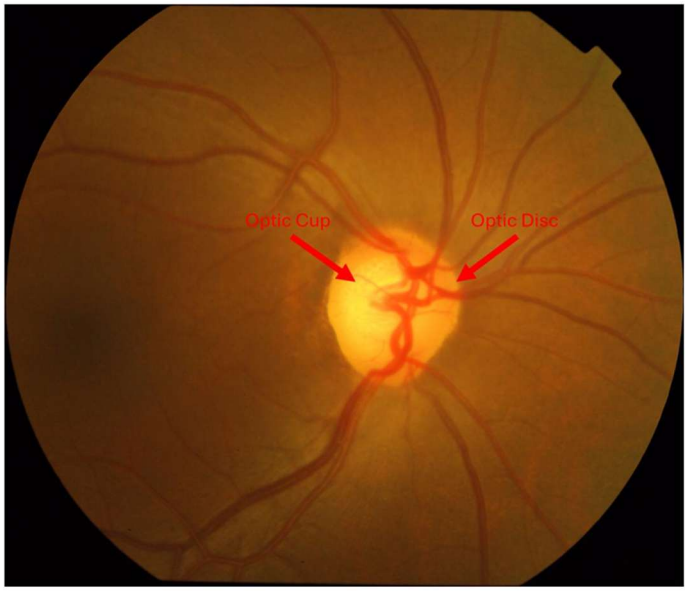

Figure 0: *Fundus Image*

Using this dataset, we will develop a segmentation pipeline that applies pre-processing techniques, connected component labeling, and post-processing refinement.

Define V-set

Preprocessing:

The images will first be converted to grayscale mode to better visualize the morphological composition of the fundus images. Then, I applied power law for contrast enhancement for easier threshold investigation when defining the V set.

Optic Disk (OD) V set:

After playing with various settings, I have found these to be the most optimal set:

$$V = \begin{cases} mean + 35 & mean < 20, power = 0.9 \\ mean + 90 & mean < 60, power = 1.2 \\ mean + 45 & Otherwise, power = 1.5 \end{cases}$$

Figure 1: *Normal OD Thresholds Comparison-Left (my settings), Right (reference softmap)*

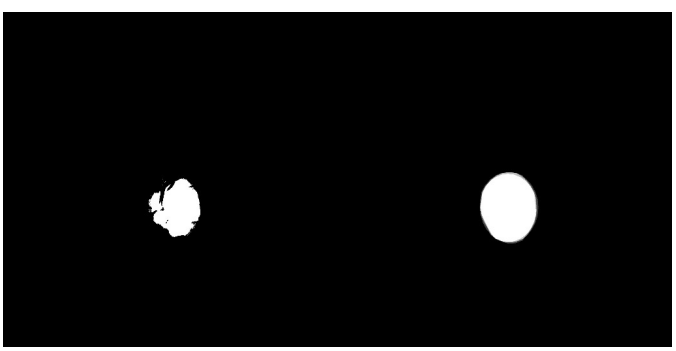

Figure 2: *Glaucoma OD Thresholds Comparison-Left (my settings), Right (reference softmap)*

Optic Cup (Cup) V set:

After playing with various settings, I have found these to be the most optimal set:

$$V = \begin{cases} mean + 40 & mean < 20, power = 2.0 \\ mean + 90 & mean < 60, power = 3.0 \\ mean + 60 & Otherwise, power = 2.0 \end{cases}$$



Figure 3: *Normal Cup Thresholds Comparison-Left (my settings), Right (reference softmap)*



Figure 4: *Glaucoma Cup Thresholds Comparison-Left (my settings), Right (reference softmap)*

Differentiating Components:

Component labeling:

I used a two pass 8-connectivity CCL function to differentiate all the objects in the binary image obtained from the thresholding processing. These steps were followed:

1) Handle the OD threshold image to label the optic disk.
2) Handle the Cup threshold image to label the optic cup.
3) The remaining portion of the image is the background label.

Postprocessing and Noise reduction:

After the labelling process, I applied a noise reduction function to improve the accuracy of the result. For noise reduction, I negated all objects with an area of less than 25 pixels.

Then I saved all pixels in each object, OD, Cup, and the background to separate text files.

Flow Diagram:

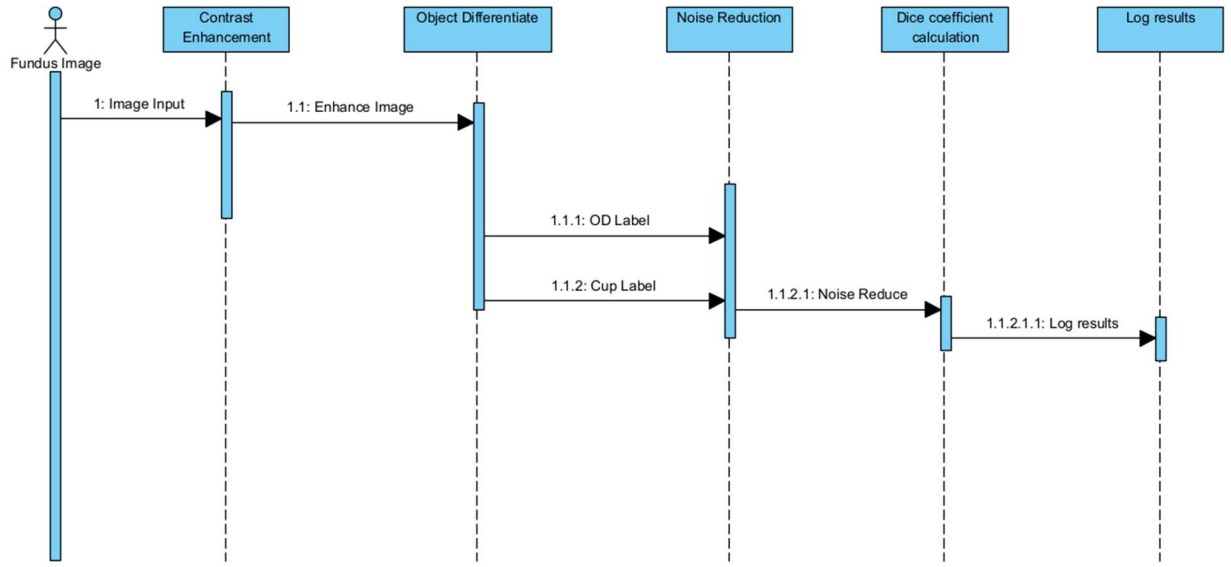

Figure 9: *Complete Flow Diagram Pipeline*

Results

To show the results, I have simply displayed the pixels in the labels as they are on a white background.

Dice coefficient calculation:

I used the method given to find the dice coefficient for each test image:

- Normal Eye Results -

OD Dice: 0.9179649233686207

Cup Dice: 0.8969819611470861

Background Dice: 0.9817183746222005

- Glaucoma Eye Results -

OD Dice: 0.5972126227288651

Cup Dice: 0.44829738539427144

Background Dice: 1.0

Outputs:

To show the results, I have simply displayed the pixels in the labels as they are on a white background.

Figure 5: *Normal Eye OD*

Figure 6: *Glaucoma Eye OD*

Figure 7: *Normal Eye Cup*

Figure 8: *Glaucoma Eye Cup*

Critical Analysis:

In this assignment, I implemented a complete segmentation pipeline for retinal fundus images using Connected Component Labelling (CCL). Through preprocessing, threshold selection, and post-processing, I was able to isolate and differentiate the Optic Disc (OD), Optic Cup, and background regions. Applying power-law transformation significantly improved contrast, which made defining effective V-sets more manageable and improved segmentation consistency.
The Dice coefficient results for the normal eye images were strong, particularly for the OD and background, indicating that the approach works reliably under less pathological conditions. However, the noticeable performance drop in the glaucoma case—especially for the cup segmentation—highlighted the limitations of simple threshold-based methods when dealing with structural variations and more complex pathological changes. This clearly shows that segmentation becomes more challenging as anatomical deformation increases.

Overall, this assignment strengthened my understanding of connected component labelling, segmentation challenges, and performance evaluation using Dice metrics. It also helped me realize that while classical image processing techniques are powerful and interpretable, they may require further refinement or more advanced methods to handle complex medical cases robustly.